

Taming of the testicular pain complicating lumbar disc herniation with spinal manipulation: A case report

Eric Chun Pu Chu

Abstract: Degenerative disease of the lumbar spine is often ignored as a potential cause of testicular pain because the exact link between the two remains uncertain.

This article reports the case of a 60y man with a 3y history of low back pain and unexplained right testicular pain for 2y. Painful symptoms were negatively affecting his social, physical, and sexual functions. After failure to achieve pain relief through multiple types of therapy, the patient sought chiropractic treatment for his condition.

Lumbar spine magnetic resonance imaging (MRI) revealed disc protrusion at the L1/L2, L3/L4, and L4/L5 segments causing thecal sac indentations. Due to the absence of direct testicular causes, the medical impression was chronic testicular pain (CTP) complicating lumbar disc disease.

The patient experienced regular improvement in his low back and testicular pain with complete resolution of both after 8 weeks of chiropractic treatment. This article describes an overlook of the aetiology of this patient's testicular pain and a successful option in treating the patient. CTP has multifactorial ethology. An excellent treatment outcome depends heavily on recognising the origin of the pain.

Indexing Terms: chiropractic; back pain; lumbar disc herniation; testicular pain; Men's Health.

Introduction

Chronic testicular pain (CTP) is a frustrating condition defined as constant or intermittent scrotal pain of at least 3 months duration that significantly interferes with daily activities. About 4.8% of men presenting at a urology clinic for other reasons also had CTP. (Ciftci et al., 2010)

The pathophysiology of CTP is multifactorial and poorly understood. There is no test to find the cause of testicular pain and the assessment is based on clinical criteria. Direct causes of CTP may include infection, tumor, testicular torsion, varicocele, hydrocele, spermatocele, and trauma. A variety of non-scrotal causes, such as ureteral stone, inguinal hernia, aortic aneurysms, and spinal disorders, can

... the orchialgia of a 39y sports coach was found to have a relationship to disc protrusion impacting the thecal sac at L3/4 and L4/5. Conservative chiropractic care to the spine and musculature resolved the complaint'

also result in referred pain to the scrotum.

Patients complaining of CTP have often been evaluated by multiple providers from different disciplines but often are left with an unexplained aetiology for their complaint. The most up-to-date guidelines on the diagnosis and management of CTP are based on expert opinion derived from small cohort studies. (Tan & Levine, 2017) This study aims to provide a better picture of an overlooked cause, proposed pathophysiology, and relevant treatment options of testicular pain.



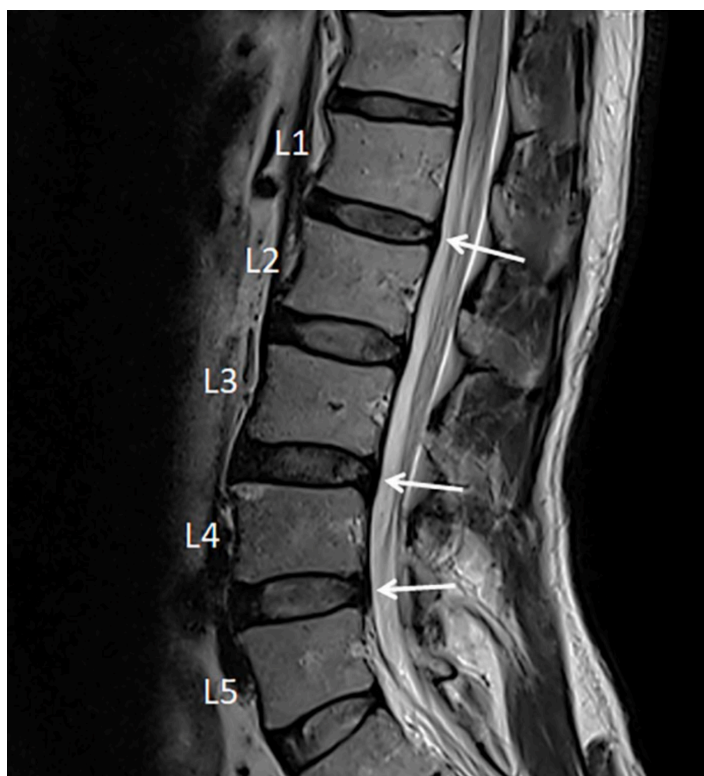
Case Report

A 60y male security guard complained of low back pain for 3y, along with right testicular pain for 2y. He had recently experienced severe pain in the right lower back down to the right buttock. Lying supine, right lumbar lateral flexion or heavy lifting could trigger right buttock pain and episodic right testicular pain.

The testicular pain was localised to his right hemiscrotum and was described as an aching sharp pain. Back and testicular pain negatively affected his social, physical, and sexual functions. Eventually, he was unable to sit up straight, get a good night's sleep, or to continue working. The patient had no previous history of localised trauma or chronic systemic diseases. Initial workup by an urologist and an orthopedist found an insignificant right renal cyst, asymptomatic left varicocele, and degenerative lumbar spine disease. A scrotal ultrasound ruled out direct testicular pathologies. For nearly 2y he had received pain medication, fluoroscopy-guided lumbar facet joint injection, exercise rehabilitation, and acupuncture, all of which failed to provide substantial, lasting symptom relief. The patient then sought chiropractic care for his condition.

Upon presentation, the size, shape, and texture of his testicles were unremarkable and even bilaterally with unrestricted movement within the scrotal sac. Point tenderness was elicited by palpating at the T12/L1 and L4/ L5 intervertebral spaces. A shock-like sensation (*Lhermitte's sign*) could be induced by spinal percussion with a reflex hammer at the T12/L1 level. Mobility restrictions were present in the lumbar spine. Sharp pain from the right thoracolumbar area down to the right buttock and testicular pain were triggered with passive lumbar extension and right lateral lumbar flexion. A tight *psoas* muscle was speculated. Pinch-roll test of the skin revealed local hyperaesthesia and tenderness over the right lumbar paraspinal region and right buttock. Lumbar spine magnetic resonance imaging (MRI; Figure 1) revealed disc desiccation (diminished signal intensity) and disc protrusion at the L1/L2, L3/L4, and L4/L5 levels, causing thecal sac indentation. In the absence of significant medical history and direct testicular causes, the subjective findings of this case were consistent with CTP caused by lumbar disc disease.

Figure 1: Sagittal T2 weighted magnetic resonance (MR) image revealed marginal osteophyte formation of the lumbar vertebrae and lumbar disc desiccation (low water content/ diminished signal intensity) with posterior protrusion at the L1/L2, L3/L4, and L4/L5 levels causing thecal indentation.



The patient underwent chiropractic treatment consisting of therapeutic ultrasound and spinal manipulation with a high-velocity, low-amplitude force applied at the thoracolumbar junction daily for 6 days. Low back pain and subsequent sleep disturbance were reduced following 1 week of treatment. His pain score declined from 9/10 to 7/10 on the numeric rating scale (NRS-11).

Subsequently, treatment sessions consisted of intermittent motorised traction (Spine Decompression Device, MID Series, WIZ Medical, Korea) focused on the T12/L1 segment, therapeutic ultrasound, and spinal manipulation. Frequency of treatments was reduced to twice weekly for the following 7 weeks. Both back and testicular pain diminished every week and were fully resolved near the end of treatment. *Oswestry Disability Index* (ODI) score decreased significantly (78% at intake, 6% at 8 weeks). He recovered and was able to resume normal daily activities with a sense of heightened well-being. A 12m follow-up phone call confirmed that the patient did not have any delayed complications, nor did he experience a recurrence of his symptoms.

Discussion

The testicles develop embryologically in the upper abdomen and descend into the scrotum shortly before birth. On their descent, the testes bring their sympathetic nerve supply with them from T10 to L1 segments and parasympathetic nerve supply from the S2 to S4 segments. (Patel, 2017; Quallich & Arslanian-Engoren, 2013) The somatic supply to the testicles and scrotum originates from the L1–L2 and S2–S4 nerve roots through the *iliohypogastric*, *ilioinguinal*, *genitofemoral*, and *pudendal* nerves. (Patel, 2017) The *genitofemoral* nerve, formed by a union of branches from the L1 and L2, splits into the genital and femoral branches after passing through the *psoas* muscle (Figure 2). The genital branch provides sensation to the *cremaster* muscle as well as the hemiscrotum in men and labia in women. The *psoas major* inserts on the lumbar discs, on the vertebral bodies, and on the transverse processes of the T12 to L5. As the *psoas* adheres to the lateral aspect of the *fibrous annulus* of the intervertebral discs, compression or inflammatory irritation derived from the lumbar discs can agitate the *psoas* muscle.

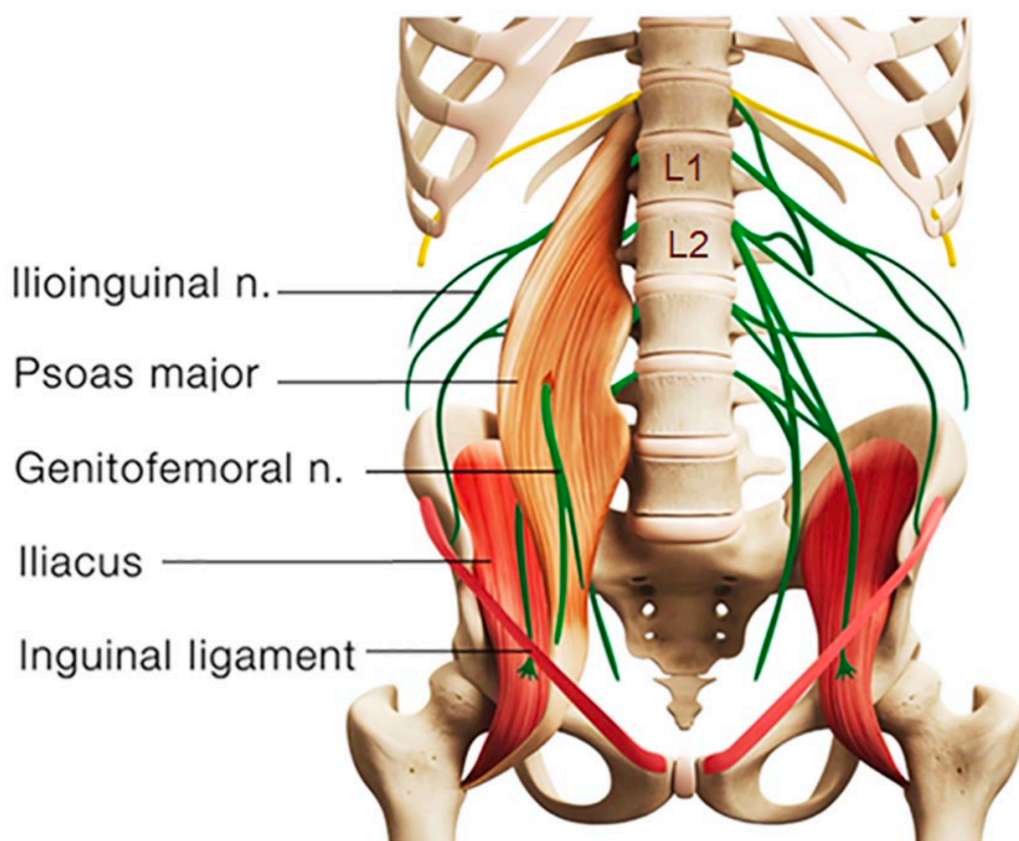


Figure 2: Schematic diagram showing anatomical relations of the lumbar spine, *psoas* muscle, and *genitofemoral* nerve. The *genitofemoral* nerve is formed from the L1 and L2 nerve roots and splits into the genital and femoral branches after passing through the *psoas* muscle. Nerve root impingement due to discitis and facet arthrosis could radiate pain into the ipsilateral testicle. A *genitofemoral* entrapment could also cause chronic testicular pain.

As shown in this case, disc protrusion at the L1/L2, L3/L4, and L4/L5 levels was observed along with right *psoas* spasticity and right testicular pain. This patient had three potential pain sources. First, lumbar radiculopathy from encroachment or irritation of the L2 nerve root could radiate pain into the ipsilateral testicle (Patel, 2017). Second, discitis and/or facet arthrosis at other levels of the patient's lumbar spine might also be capable of referring pain, transmitted non-segmentally via the paravertebral sympathetic chain to the L1–L2 nerve roots and in the genitofemoral nerve to the testicle. (Doubleday et al., 2003; Peng et al., 2014) Third, the *genitofemoral* nerve penetrates the *psoas* muscle before splitting into the genital and femoral branches (Figure 2). *Genitofemoral* entrapment at the spastic *psoas* might also be involved in the advent of testicular pain. (Masarani & Cox, 2003) Many of these hypotheses, as in this case, remain unconfirmed.

The pathophysiology of testicular pain is multifactorial and poorly understood. Diagnostic and treatment recommendations are based on expert opinion derived from small cohort studies. (Patel, 2017) The appropriate approach to a patient presenting with CTP is to first rule out the possibility of serious pathology or red flag symptoms. When imaging is deemed necessary, a high-resolution scrotal ultrasound with color-flow Doppler is the primary modality used to detect and diagnose abnormalities within the scrotum. There can often be straightforward explanations for the CTP such as varicocele, infection, tumor, or referred pain from non-scrotal sources, but more often the aetiology remains unexplained. (Quallich & Arslanian-Engoren, 2013) Because of the overlapping sensory innervations and anatomic variability, it is difficult to differentiate the particular nerve involvement in cases of testicular pain.

The first step in the management of CTP with no red flag signs remains conservative in nature. Consideration should include the use of antibiotics, nonsteroidal anti-inflammatory medications, pelvic floor physical therapy, or spermatic cord block. When conservative measures have failed, microsurgical testicular denervation and orchiectomy have been described as procedures of last resort. Unsuccessful recognition of the causative factors for CTP often leads to surgical failure, poor outcomes, and years of psychological distress. (Doubleday et al., 2003)

There is a scarcity of data on the association of CTP with degenerative lumbar spine disease. Case reports (Doubleday et al., 2003; Rowell & Rylander, 2012) reveal significant efficacy of manipulative therapies for alleviating testicular pain of spinal origin. According to the *Clinical Guidelines for Diagnosis and Treatment of Lumbar Disc Herniation With Radiculopathy* (Kreiner et al., 2014) spinal manipulation is an option for radiculopathy caused by discogenic disease. Remission of CTP observed in the present case appears to support that spinal manipulation could be a treatment regimen for testicular pain from this cause.

The exact mechanism underlying the action of chiropractic adjustments for the relief of discogenic pain remains unclear. The trial of Chiropractic in this case consisted of therapeutic ultrasound and spinal manipulation, along with intermittent motorised lumbar traction. Reported thermal effects of ultrasound upon tissue include raised tissue temperature, enhanced circulation, reduced muscle spasm, and increased extensibility of collagen fibres and a pro-inflammatory response. (Speed, 2001)

Biomechanical effects of chiropractic manipulation on symptom relief include relaxation of hypertonic musculature, release of entrapped nerves, disruption of periarticular adhesions, and restoration of spinal alignment. (Onel et al., 1989) Lumbar traction is a form of decompression therapy, creating increased space and negative pressure of the intervertebral space. Intermittent mechanical traction can facilitate diffusion of nutrients for the disc and initiate the healing process. The main limitation of the present study is that the cause of testicular pain and mechanism of symptom relief are still uncertain without a control group. As a study retrospective in nature, the items regarding diagnosis, management, and outcome monitoring were not necessarily comprehensive.

Larger scale studies regarding the efficacy of nonsurgical regimens for CTP are needed to provide corroboration.

Conclusion

Testicular pain arises from muscle, joint, or nerve issues that cannot easily be identified. Recognition of pain referral patterns and appropriate intervention are essential for the management of testicular pain. Once pathologies have been ruled out a trail of Chiropractic management is warranted.



Eric Chun Pu Chu

BSc, DC, MHA, PhD (Hon), ICCSP, FRCC

Hong Kong, China

eric@nymg.com.hk

Cite: Chu ECP. Taming of the testicular pain complicating lumbar disc herniation with spinal manipulation: A case report. *Asia-Pac Chiropr J.* 2023;3.4. URL apcj.net/Papers-Issue-3-4/#ChuTamingTesticularPain

About

Originally published by the *American Journal of Men's Health* as Chu ECP. Taming of the testicular pain complicating lumbar disc herniation with spinal manipulation. *Am J Men's Health.* 2020;Jul-Aug:1-4.

We acknowledge the *American Journal of Men's Health* as the original publisher and based on the importance of this information for our audience of chiropractic readers, we reproduce this version under the terms of the Creative Commons Attribution License CC-BY 4.0., which permits unrestricted use, distribution, and reproduction in any medium, provided the original author and source are credited.
We have duly credited *Am J Mens Health*.

The author holds patient consent for this use of their information.
No external funding was received. There are no known conflicts of interest.

References

- Ciftci, H., Savas, M., Yeni, E., Verit, A., & Topal, U. (2010). Chronic orchialgia and associated diseases. *Current Urology*, 46(2), 67–70. <https://doi.org/10.1159/000253415>
- Doubleday, K. L., Kulig, K., & Landel, R. (2003). Treatment of testicular pain using conservative management of the thoracolumbar spine: A case report. *Archives of Physical Medicine Rehabilitation*, 84(12), 1903–1905. [https://doi.org/10.1016/S0003-9993\(03\)00283-1](https://doi.org/10.1016/S0003-9993(03)00283-1)
- Kreiner, D. S., Hwang, S. W., Easa, J. E., Resnick, D. K., Baisden, J. L., Bess, S., Cho, C. H., DePalma, M. J., Dougherty, P., Fernand, R., Ghiselli, G., Hanna, A. S., Lamer, T., Lisi, A. J., Mazanec, D., Meagher, R. J., Nucci, R. C., Patel, R. D., Sembrano, J. N. . . . North American Spine Society. (2014). An evidence-based clinical guide- line for the diagnosis and treatment of lumbar disc hernia- tion with radiculopathy. *Spine Journal*, 14(1), 180–191. <https://doi.org/10.1016/j.spinee.2013.08.003>
- Masarani, M., & Cox, R. (2003). The aetiology, patho- physiology and management of chronic orchialgia. *BJU International*, 91(5), 435–437. <https://doi.org/10.1046/j.1464-410X.2003.04094.x>
- Onel, D., Tuzlaci, M., Sari, H., & Demir, K. (1989). Computed tomographic investigation of the effect of traction on lumbar disc herniations. *Spine*, 14(1), 82–90. <https://doi.org/10.1097/00007632-198901000-00017>
- Patel, A. P. (2017). Anatomy and physiology of chronic scrotal pain. *Translational Andrology and Urology*, 6(Suppl 1), S51–S56. <https://doi.org/10.21037/tau.2017.05.32>
- Peng, B., Li, D., & Pang, X. (2014). Degenerative lumbar spon- dylolisthesis with testicular pain. *Pain Medicine*, 15(1), 169–170. <https://doi.org/10.1111/pme.12246>
- Quallich, S. Q., & Arslanian-Engoren, C. (2013). Chronic tes- ticular pain in adult men: An integrative literature review. *American Journal of Men's Health*, 7(5), 402–413. <https://doi.org/10.1177/1557988313476732>
- Rowell, R., & Rylander, S. (2012). Low-back pain, leg pain, and chronic idiopathic testicular pain treated with chiropractic care. *Journal of Alternative and Complementary Medicine*, 18(4), 420–422. <https://doi.org/10.1089/acm.2010.0698>
- Speed, C. A. (2001). Therapeutic ultrasound in soft tissue lesions, *Rheumatology*, 40(12), 1331–1336. <https://doi.org/10.1093/rheumatology/40.12.1331>
- Tan, W. P., & Levine, L. A. (2017). What can we do for chronic scrotal content pain? *World J Men's Health*, 35(3), 146– 155. <https://doi.org/10.5534/wjmh.17047>