

Resolution of disc-related peripheral oedema following Chiropractic treatment: A case report

Duncan Jack

Narrative: A 36-year-old female patient with no significant medical history suffered a fall with resultant stabbing back pain and herniated nucleus pulposus of L4/L5 and L5/S1 with severe discomfort and moderate non-pitting oedema in her legs, worse on the right, affecting her quality of life. A constant, deep ache in her left lower abdominal quadrant and bilateral inguinal region was also present. Deep vein thrombosis and underlying pathology were ruled out.

Physical examination revealed a non-pitting oedematous right lower leg with diminishment of crude touch and pinwheel sensations, absent patellar and calcaneal deep tendon reflexes, and significant mechanical and positional distortions with iliopsoas dysfunction.

Clinical metrics were monitored throughout her 11-treatment care protocol. Significant reduction in back, leg and left abdominal pain was reported within 4 treatments with improvements in movement ability and functional daily tasks noted with a reduction in measured oedema and mechanical dysfunction. The previously absent calcaneal reflex became detectable bilaterally by the end of the initial 8 treatment phase. This was compared to the only other case of peripheral oedema subsidence following Chiropractic care reported in literature where the proposed improvement mechanism was attributed to autonomic regulatory effects of Chiropractic adjustments.

This report proposes a haemodynamic-related cause of oedema due to compression of the common femoral vein secondary to mechanical dysfunction and prolonged hip extension. The mechanism by which Chiropractic treatment is effective in this case is considered to be in the treatment of underlying mechanical dysfunction.

Indexing Terms: Chiropractic; subluxation; oedema; disc herniation; diversified.

Case presentation

A 36-year-old, Dutch, female patient reported to a chiropractic practice with the primary complaint of severe, constant, bilateral heaviness and squeezing pain with visible swelling in both lower legs, albeit significantly worse on the right, with the presence of sharp low back pain. Focal pain was demonstrated in the right lateral lower leg between the knee and ankle.

Symptomatology included a constant, deep ache in the left lower abdominal quadrant extending to the inguinal region. Her symptoms were reported to impede her ability to stand, walk, exercise, sleep and work as a

... All activities of daily life had returned to normal by the 3-month visit, with residual discomfort rated a 1 on the NRS



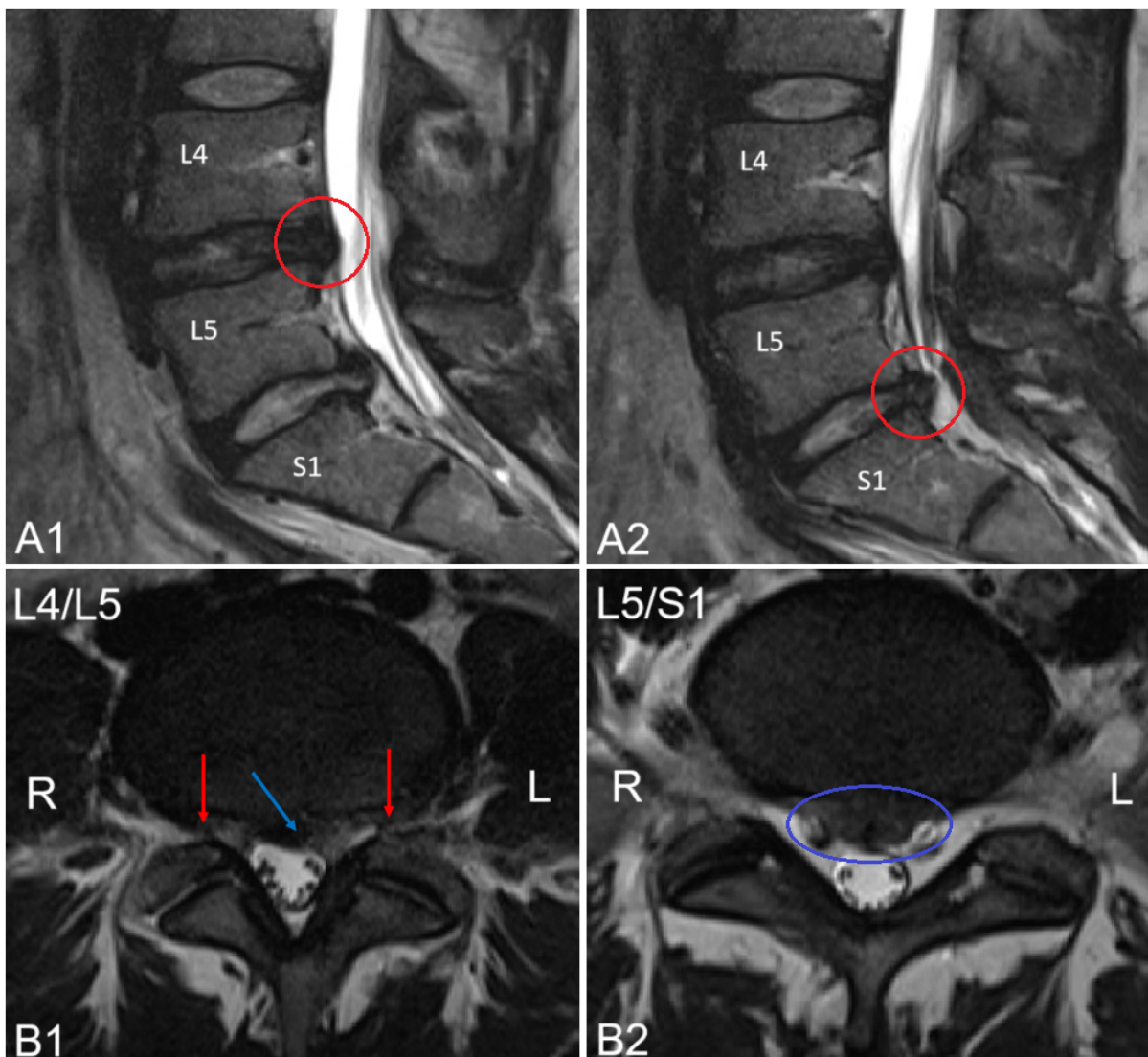
teacher. Pain was rated 7 overall on the numerical rating scale (NRS). The symptoms began within 24 hours after a fall while hiking and were present for 14 months at the time of reporting.

The patient was first assessed by a GP, followed by a neurologist who ordered magnetic resonance imaging (MRI) of the lumbar spine. The possibility of deep vein thrombosis and cardiovascular aetiologies were excluded by a cardiologist. The patient was otherwise in good health, took no medication and had no significant medical history besides having had two caesarean sections. Susceptibility to oedema in the patient's father was mentioned but could not be further described or substantiated. The patient had no prior experience of Chiropractic treatment.

Imaging

MRI revealed a (left) paramedian herniated nucleus pulposus (HNP) at L4/L5 with narrowing of the lateral recess and perineural space bilaterally. A central HNP was also present at L5/S1 without lateral recess encroachment (see Figure 1). No medication was prescribed. The pain was reported to only intensify over time despite prescribed physiotherapy and use of compression stockings.

Figure 1: T2-weighted MRI imaging of the lumbar spine in the sagittal view (A1 and A2) and axial view (B1 and B2). A left para-sagittal HNP is present at L4/L5 in A1 (red circle) and B1 (blue arrow) with narrowing of the lateral recess bilaterally in B1 (red arrows). A mid-sagittal HNP is present at L5/S1 in A2 (red circle) and B2 (blue oval).



Physical examination

An antalgic gait was present with the left hip in a visibly flexed position. Neutral standing position was not achievable in the sagittal and frontal planes due to pain.

When supine, the left ASIS and greater trochanter of the femur was observed in a superior position to that on the right. Leg length was measured from the anterior superior iliac spine (ASIS) to medial malleolus of the ankle which showed a 0.5cm structural variance (left short) and from umbilicus to medial malleolus showing a 1.5cm shorter on the left.

On palpation, the skin of the right lower leg was tight, unyielding and uncomfortable for the patient with bony anatomy of the ankle being less prominently visible on the right as opposed to the left with no indication of pitting on focal compression at the talus, distal or proximal tibia. Sensation in the entire right lower leg and foot was mildly decreased in crude touch and pinwheel sensation compared to the left. Myotomes were normal bilaterally. Patellar and calcaneal reflexes were absent bilaterally. Lower leg circumference measured at the widest point of the calf (7cm inferior to the tibial tuberosity) demonstrated 2cm greater girth on the right. Measurements were rounded to the closest 0.5cm.

Back pain severely limited mobility in four movements:

- ▶ Standing torso forward flexion;
- ▶ seated torso rotation to the right;
- ▶ left sided hip flexion, abduction and external rotation (FABER).

Maximum active straight leg raises (ASLR) measured with a digital bevel protractor (rounded to the nearest 5°) were recorded at 50° on the left and 20° on the right. Significant tenderness was present on palpation of the left lower abdominal quadrant, bilateral inguinal regions, left sacroiliac joint, right superior fibula head and right calcaneal tendon, with muscular trigger points detected in the left iliopsoas, left piriformis, and right gluteus medius musculature.

Range of motion (ROM) restrictions were detected in the left sacroiliac (SI) joint and right superior fibular head. Thecal sac impingement tests did not yield pain distinguishable from pain at rest. No peritoneal or splenic irritation or abnormalities were detected. Cardiovascular examination was unremarkable.

Intervention

The patient was treated with diversified Chiropractic as high-velocity, low-amplitude adjustments of chiropractic subluxation complexes. L5 postero-anterior (PA) on the right using a push-pull technique in side posture position; left sacroiliac joint in flexion in side posture; right hip in long-axis while supine, right fibular head in postero-anterior glide while supine with a flexed knee; right talocrural joint in long-axis while supine and the left first tarsometatarsal joint in dorsiflexion while supine. Flexion-extension, seated lumbopelvic mobility exercises were prescribed and education was dispensed on sitting and standing ergonomics.

Treatment sessions were conducted once weekly for a total of eight weeks, thereafter treatments were conducted at increasing intervals, namely 2 weeks, followed by a period of 4 weeks and a further 6 weeks thereafter (3 months after the initial visit) with clinical metric measured at presentation, at the end of the 8-week treatment plan, and at the 3 months follow up (see table 1).

Outcomes

At the second visit the patient reported moving more comfortably with less pressure in the right lower leg. Calf circumference had a 50% reduction in asymmetry, quantified at 1cm. Right torso rotation had marginally improved. SLR testing was unchanged. Dynamic ischaemic

compression of the left piriformis and right gluteus medius trigger points was added to the treatment regimen from that point.

Recreational cycling for 30 minutes was first reported as possible and comfortable on visit three. Subsidence of the left lower abdominal pain and sleeping throughout the night was reported at visit 4. Absence of abdominal pain and a sense of stability while standing and walking was described at visit 5.

Table 1: Objective evaluation metrics taken at the beginning and end of the weekly treatment plan and at 3 months after the initial presentation.

Findings / Visit:	1 st (Initial)		8 th		3-month FU	
	L	R	L	R	L	R
Side						
Calf circumference (cm)	41.5	43.5	41.5	42	41.5	42.5
Maximum SLR (degrees)	50	20	70	60	70	65
Umbilicus to medial malleolus (cm)	100.5	102	101.5	102	101.5	102
ASIS to medial malleolus (cm)	89.5	90	89.5	90	89.5	90
Reflex: Patella	0	0	0	0	0	0
Reflex: Calcaneal	0	0	+1	+1	+1	+1

By visit 8 resolution of right leg symptoms was reported, with only light nagging discomfort in the low back and left sacroiliac region. Standing position was neutral without visible compensation. Seated torso rotation was painless and equal bilaterally. Previously hypertonic lumbopelvic musculature was only mildly uncomfortable on palpation and calcaneal reflexes had become detectable (+1) bilaterally. All activities of daily life had returned to normal by the 3-month visit, with residual discomfort rated a 1 on the NRS. Progress measurements from the initial visit, 8th visit and 3-month follow-up are displayed in Table 1.

Discussion

The aim of this discussion is to identify possible mechanisms by which Chiropractic treatment may alleviate peripheral oedema. In the case of unilaterally focussed oedema in this patient with a traumatic lumbar disc herniation, the non-pitting nature and absence of co-morbidities suggest a local obstructive or compressive aetiology affecting lymphatic return in the lower limbs as opposed to a systemic cause of oedema. (Ely et al., 2006; Patel et al., 2022) The case is examined further on the basis of clinical and radiological findings.

Clinical and radiological findings

The patellar reflex functions through synapses at L2, L3 and (predominantly) L4 and the calcaneal reflex synapses at S2 and (predominately) S1. (Campbell & Barohn, 2020) The patient's radiological findings of HNP with bilateral lateral recess narrowing at L4/L5 and a central HNP at L5/S1 account for the patient's stabbing back pain and suggest a disturbance in the reflex arc with a result of loss of the patellar and calcaneal reflexes bilaterally. (Campbell & Barohn, 2020; Traves et al., 2013) Lumbosacral plexus irritation secondary to sacroiliac joint dysfunction may also result in the absence of the calcaneal reflex and occurs through the movement of inflammatory substrate into the periarticular space that impacts neural elements of the

lumbosacral plexus. (Deyo & Mirza, 2016; Oliver et al., 2021) The clinical findings of the flexed left hip including patterns of pain, movement restrictions and hypersensitivity in the left lower quadrant and inguinal region are consistent with *iliopsoas* muscle hypertonicity, (Anderson, 2016) with the lack of pelvic symmetry and decreased lumbar rotation being consistent with common findings in patients with lumbar disc herniations. (Kuligowski & Sipko, 2021)

Comparative case

Chu and Wong (2018) described the only previously documented case of 'discogenic' oedema in a 40 year old female that subsided during the course of a 22-treatment Chiropractic care protocol.

The mechanism of improvement was proposed to be improved lymphatic function due to regulation of the autonomic nervous system as a result of chiropractic adjustments, although determination became difficult with the possibility of iatrogenic oedema from prescribed medication.

The regulatory effects of manipulative therapy on the autonomic nervous system are mixed in literature and focus mainly on heart rate variability, blood pressure, skin temperature and respiratory rate. Effects specifically relating to rates or quality of lymphatic drainage have yet to be investigated. (Alanazi et al., 2024; Araujo et al., 2019) Considering this in light of the current case report with the non-pitting nature of oedema, absence of co-morbidities and iatrogenic causes, other potential mechanisms of improvement must be considered.

Haemodynamics

The relative position of the SI-hip complex in extension on the right and in flexion on the left can give rise to abnormal force distribution patterns in the pelvis, seen when the common femoral artery is compressed by the superior pubic ramus during hip extension. (Cheng et al., 2020) While this effect is usually transient during movement, prolonged or suboptimal alignment of the SI-hip complex in a constant extended position may reduce venous return from the lower extremities by impeding venous outflow and increasing venous stasis. (Cheng et al., 2020; Cheng et al., 2023) Although the lymphatic system functions to return 2 to 3 litres of fluid to the cardiovascular system over a 24-hour period, (Tatlıcı & Cakmakçı, 2021) altered hydrostatic pressures due to venous stasis give rise to the movement of fluid from the capillaries into the interstitium, which exceeds the lymphatic system's ability to remove it, resulting in fluid accumulation in the soft tissues. (Patel et al., 2022; Scherer & Khilnani, 2021)

Hypothesis

Postulating that chronic compensatory extension of the SI-hip complex is the cause of lymphoedema and resultant non-pitting oedema, it stands to reason that Chiropractic adjustments contribute toward a more neutral posture, reducing the pressure effect that the superior pubic ramus exerts on the common femoral vein thus addressing the cause of the resultant oedema. This effect is further reinforced by an adjunctive mobility program. (Smith et al., 2024; Tatlıcı & Cakmakçı, 2021)

This process as a proposed mechanism by which Chiropractic treatment can positively affect peripheral oedema is consistent with the return of the bilateral calcaneal reflex according to the concept of reduction of lumbosacral plexus irritation which may be secondary to sacroiliac dysfunction. (Oliver et al., 2021) Furthermore, the non-dermatomal pattern of sensory loss in the right lower leg experienced by the patient can also be attributed to localised oedema and increased pressure on the peripheral nerves. (Biso & Munakomi, 2022)

Conclusion

The effects of mechanical dysfunction as a compensatory mechanism following disc herniation and nerve root entrapment may have a direct impact on the function and patency of the common femoral vein, leading to limb oedema. Chiropractic care in the treatment of mechanical lumbopelvic distortions may offer a significant, effective solution by decreasing the pressure effect that the superior pubic ramus exerts on the common femoral vein.

It is recommended that further research be conducted to test this hypothesis.

Duncan Jack
MTEch, DC, Dip Sports Med
Private practice of Chiropractic
Haarlem, the Netherlands
duncanjack101@gmail.com

Cite: Jack D. Resolution of disc-related peripheral oedema following Chiropractic treatment A case report. *Asia-Pac Chiropr J.* 2025;5.4. www.apcj.net/papers-issue-5-4/#JackOedema

References

- Alanazi, M. S., Degenhardt, B., Franklin, G., Jacobson, E., Fritz, S., Kettner, N., Reed, W. R. (2024). Autonomic nervous system and viscera-related responses to manual therapy: A narrative overview. *International Journal of Osteopathic Medicine*, 54, 100735. DOI: <https://doi.org/10.1016/j.ijosm.2024.100735>
- Anderson, C. N. (2016). Iliopsoas: Pathology, Diagnosis, and Treatment. *Clinics in sports medicine*, 35(3), 419-433. DOI: <https://doi.org/10.1016/j.csm.2016.02.009>
- Araujo, F. X., Ferreira, G. E., Angellos, R. F., Stieven, F. F., Plentz, R. D. M., & Silva, M. F. (2019). Autonomic effects of spinal manipulative therapy: systematic review of randomized controlled trials. *Journal of manipulative and physiological therapeutics*, 42(8), 623-634. DOI: <https://doi.org/10.1016/j.jmpt.2018.12.005>
- Biso, G., & Munakomi, S. (2022). Neuroanatomy, neurapraxia. StatPearls, NCBI Bookshelf., National Library of Medicine. <https://www.ncbi.nlm.nih.gov/books/NBK557746>
- Campbell, W., & Barohn, R. (2020). DeJong's The Neurologic Examination (C. Teja, Ed. 8th ed.), 571-587. Wolters Kluwer. <https://www.wolterskluwer.com/en/solutions/ovid/dejongs-the-neurologic-examination-4853>
- Cheng, C. P., Dua, A., Suh, G.-Y., Shah, R. P., & Black, S. A. (2020). The biomechanical impact of hip movement on iliofemoral venous anatomy and stenting for deep venous thrombosis. *Journal of Vascular Surgery: Venous and Lymphatic Disorders*, 8(6), 953-960. DOI: <https://doi.org/10.1016/j.jvsv.2020.01.022>
- Cheng, C. P., Suh, G. Y., Jalaie, H., & Barbati, M. E. (2023). Stent deformations in the common iliac and iliofemoral veins as a result of hip flexion and extension. *J. Vasc Surg Venous Lymphat Discord*, 11(5):1014-1022. DOI: <https://doi.org/10.1016/j.jvsv.2023.02.010>
- Chu, E. C. P., & Wong, J. T. H. (2018). Subsiding of Dependent Oedema Following Chiropractic Adjustment for Discogenic Sciatica. *European Journal of Molecular & Clinical Medicine*, 5(1), 1-4. https://www.researchgate.net/publication/324598682_Subsiding_of_Dependent_Oedema_Following_Chiropractic_Adjustment_for_Discogenic_Sciatica
- Deyo, R. A., & Mirza, S. K. (2016). Herniated lumbar intervertebral disk. *New England Journal of Medicine*, 374(18), 1763-1772. DOI: <https://doi.org/10.1056/NEJMc1512658>
- Ely, J. W., Osheroff, J. A., Chambliss, M. L., & Ebell, M. H. (2006). Approach to Leg Edema of Unclear Etiology. *The Journal of the American Board of Family Medicine*, 19(2), 148. DOI: <https://doi.org/10.3122/jabfm.19.2.148>

Kuligowski, T., & Sipko, T. (2021). Lumbopelvic biomechanics in patients with lumbar disc herniation-prospective cohort study. *Symmetry*, 13(4), 602. DOI: <https://doi.org/10.3390/sym13040602>

Oliver, J. D., Lessing, N. L., Mushlin, H. M., Olexa, J. R., Crandall, K. M., & Sansur, C. A. (2021). Radiculopathy with concomitant sacroiliac dysfunction and lumbosacral degenerative disease: illustrative case. *Journal of Neurosurgery: Case Lessons*, 2(12), CASE21102, 22021. DOI: <https://doi.org/10.3171/CASE21102>

Patel, H., Skok, C., & DeMarco, A. (2022). Peripheral Edema: Evaluation and Management in Primary Care. *Am Fam Physician*, 106(5), 557-564. <https://www.aafp.org/pubs/afp/issues/2022/1100/peripheral-edema.html>

Scherer, K., & Khilnani, N. (2021). Evaluation and management of patients with leg swelling: Therapeutic options for venous disease and lymphedema. *Seminars in Interventional Radiology*, 38(02), 189-193. DOI: <https://doi.org/10.1055/s-0041-1727162>

Smith, B., Park, J., Landi, J. L., McConnell, B., Rahman, A., Omari, A. R., Kim, B. (2024). Chronic Edema Management of the Lower Extremities. *Cureus*, 16(7), e63840. DOI: <https://doi.org/10.7759/cureus.63840>

Tatlıcı, A., & Cakmakçı, O. (2021). Exercise and Lymphatic System. *Turkish Journal of Sport and Exercise*, 23(2), 150-154. <https://dergipark.org.tr/en/pub/tsed/issue/64815/957914>

Trayes, K. P., Studdiford, J. S., Pickle, S., & Tully, A. S. (2013). Edema: diagnosis and management. *American family physician*, 88(2), 102-110. <https://www.aafp.org/pubs/afp/issues/2013/0715/p102.html>